

Providence St. Joseph Health

## Providence St. Joseph Health Digital Commons

---

[View All Washington/Montana GME](#)

[Washington/Montana GME](#)

---

2022

### SCREENING FOR MIXED-ETIOLOGY PLEURAL EFFUSION USING POINT OF CARE ULTRASOUND

Samuel Eglin

Abby Velarde

Follow this and additional works at: [https://digitalcommons.psjhealth.org/gme\\_wamt\\_all](https://digitalcommons.psjhealth.org/gme_wamt_all)



Part of the [Cardiology Commons](#)

---



# SCREENING FOR MIXED-ETIOLOGY PLEURAL EFFUSION USING POINT OF CARE ULTRASOUND

Samuel Eglin, MD, Spokane Internal Medicine Residency,  
Abby Velarde, MS3, WSU Elson S. Floyd College of Medicine

Elson S. Floyd  
College of Medicine

## Introduction

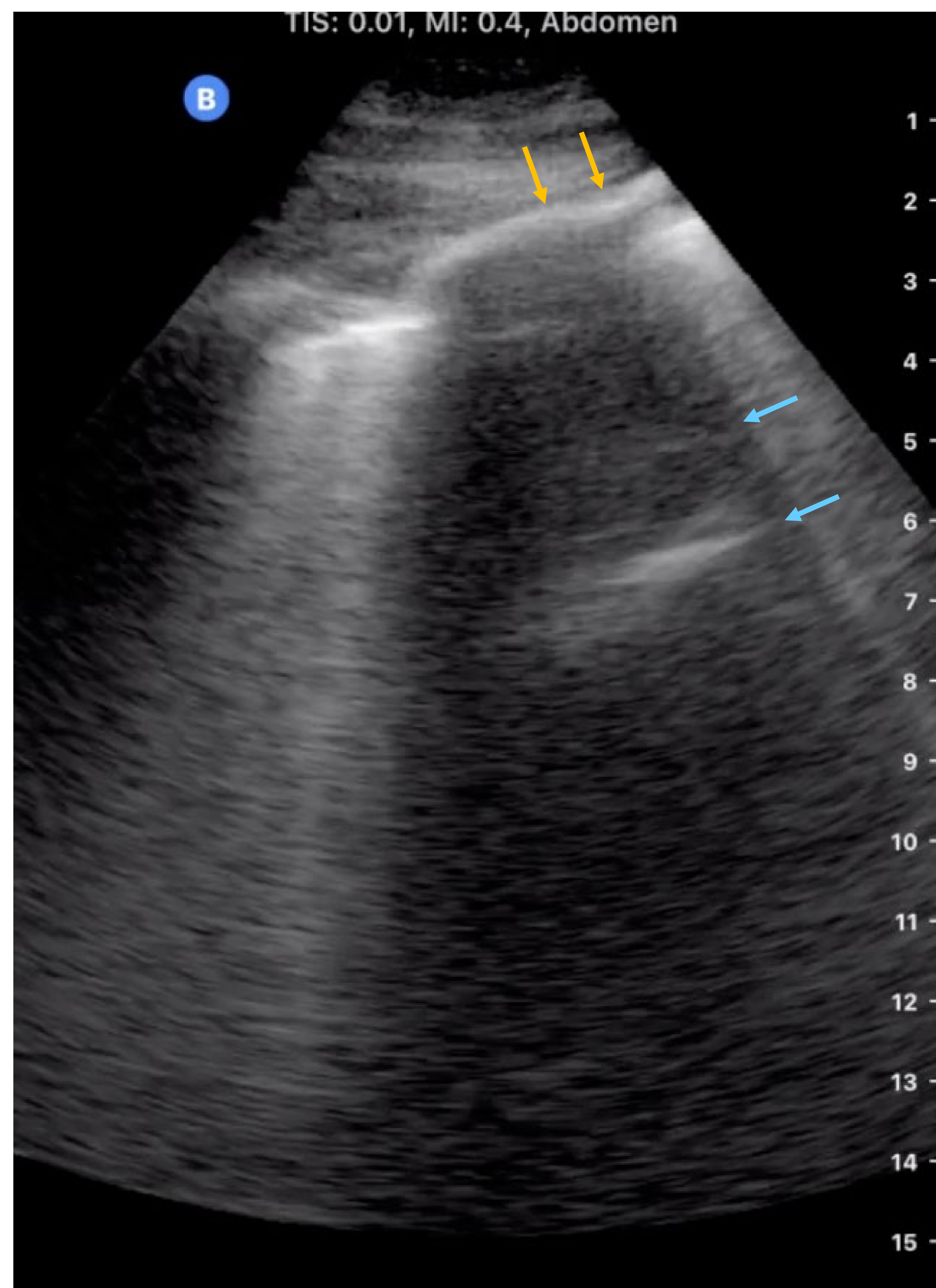
Point of care ultrasound (POCUS) can be a useful bedside tool in deciding whether diagnostic thoracentesis is warranted in patients presenting with pleural effusion. Patients with a clinical history suggesting transudative etiology of a pleural effusion may not require thoracentesis. However, certain sonographic characteristics of pleural effusions are strongly associated with exudative processes and may indicate thoracentesis regardless of clinical history. Specifically, complex septated appearance of pleural fluid has a positive likelihood ratio of 7.33 for exudative processes [1] and pleural thickness  $>1$ cm has a positive likelihood ratio of 8.4 for malignant pleural effusion [2]. In addition, an echogenic swirling pattern suggests malignant pleural effusion, but has limited positive likelihood ratio of 2.96 [3, 4]. Notably, echogenicity alone appears to correlate poorly to whether an effusion is transudative, exudative, or malignant and should not significantly influence clinical decision making [5]. Here we present an interesting case of a mixed-etiology pleural effusion whose clinical course was significantly altered after sonographic signs of malignant pleural effusion were identified using POCUS.

## Case

An 87-year-old-woman with history of congestive heart failure (CHF) and previously-diagnosed 1 cm pancreatic head mass was admitted for acute hypoxemic respiratory failure in the setting of volume overload and bilateral pleural effusions following several weeks of non-compliance with her outpatient diuretic regimen. Given a clear clinical explanation for a transudative CHF-process driving her pleural effusion a diagnostic thoracentesis was not initially performed. Within 48 hours of IV diuresis the patient was no longer requiring supplemental oxygen and expressed

## Case continued...

expressed to the internal medicine team that she was eager to return home. However, during POCUS teaching rounds prior to discharge she was incidentally found to have an echogenic pleural effusion with fibrinous-appearing septations and pleural thickness of approximately 1 cm. Due to these findings and patient's history of pancreatic head mass a diagnostic thoracentesis was ordered. Pleural fluid cytology revealed metastatic pancreatic adenocarcinoma—indicating Stage IV disease with  $<6$  month life-expectancy. With this new diagnosis patient was able to participate in goals of care while hospitalized and ultimately chose to discharge to home-hospice care.



## Discussion

This case is an excellent illustration of how sonographic characteristics of pleural effusion on POCUS can guide the decision to pursue a diagnostic thoracentesis. Here, incidental identification of pleural thickening and fibrinous septations on point of care ultrasound lead to a diagnostic thoracentesis which revealed Stage IV pancreatic adenocarcinoma. This diagnosis provided the patient with valuable prognostic information in deciding her course of care and likely saved her repeated hospitalization. This case also emphasizes that patients with clinical histories suggesting transudative pleural effusion should still be screened for high-risk sonographic features in order to avoid missing mixed-etiology pleural effusions.

## ◀ Figure 1:

Point of care ultrasound demonstrating an echogenic pleural effusion with fibrinous septations (blue) and pleural thickness at 1 cm (orange), prompting further workup.

## Sources

1. *Transudative From Exudative Pleural Effusion*. Chest, 2020. **158**(2): p. 692-697.
2. Qureshi, N.R., N.M. Rahman, and F.V. Gleeson, *Thoracic ultrasound in the diagnosis of malignant pleural effusion*. Thorax, 2009. **64**(2): p. 139-43.
3. Chian, C.F., et al., *Echogenic swirling pattern as a predictor of malignant pleural effusions in patients with malignancies*. Chest, 2004. **126**(1): p. 129-34.
4. Chian, C.F., et al., *Echogenic swirling pattern, carcinoembryonic antigen, and lactate dehydrogenase in the diagnosis of malignant pleural effusion*. Sci Rep, 2022. **12**(1): p. 4077.
5. Asciak, R., et al., *Prospective Analysis of the Predictive Value of Sonographic Pleural Fluid Echogenicity for the Diagnosis of Exudative Effusion*. Respiration, 2019. **97**(5): p. 451-456.